



PATIENT

Molly Rivas

SPECIES

Canine

BREED

Pub Mix

SEX

Female Spayed

AGE

11.3 years

WEIGHT

48lbs

INTERPRETED BY

Maggie Machen Lamy,
DVM, DACVIM
(Cardiology)

IMAGING PERFORMED BY

Kelly Romero, DVM

HOSPITAL NAME

Countryside Animal
Hospital

REFERRING VET

Dr. Latelle

INVOICE

46251

DATE

12/17/25

PRESENTING CLINICAL SIGNS

History: Possible grade 2-3/6 heart murmur with audible clicks on left side. BP: 190mmHg - nervous. Slowing down on walks.

ECHOCARDIOGRAM FINDINGS

2D, m-mode, color flow and doppler imaging is available. Mild diffuse thickening of mitral valve leaflets with no prolapse into the left atrial lumen. Trace/mild eccentric mitral regurgitation with no left atrial dilation (LA:Ao <1.4). Normal LV diameter with adequate myocardial function. The tricuspid valve appears mildly thickened with no significant tricuspid regurgitation. Normal right atrial and ventricular diameter and morphology indicating no overt evidence of pulmonary arterial hypertension. The pulmonic and aortic valves are normal in morphology and mobility. Normal pulmonic and aortic outflow velocities with laminar flow. No obvious aortic and trace pulmonic insufficiency. No pericardial or pleural effusion noted. No obvious cardiac masses.

CARDIAC CHART

CANINE CARDIAC PARAMETERS	MR VMAX (m/s)	TR VMAX (m/s)	LA/AO (Boon method)	LA/AO (Heart Base; Swe)	FS (%)	EF (%)	EPSS (cm)
NORMAL PARAMETER	4.5-5.5	<2.7	1.3	<1.6	28-40	40-100	<0.6
PATIENT	NM	NA	1.7	1.3	43	74	0.4
CANINE CARDIAC PARAMETERS	HR (BPM)	AV VMAX (m/s)	PV MAX (m/s)	BODY WEIGHT (kg)	LA 2D short axis Base view (cm)	LVIDd Avg; 2D and m-mode short axis (cm)	LVIDs Avg; 2D and m-mode short axis (cm)
NORMAL PARAMETER	50-100	0.7-1.7	0.7-1.6	BELOW	BELOW	BELOW	BELOW
PATIENT	NM	1.4	1.1	21.8	3.0	4.4	2.6
*Normal chamber parameters expressed as a mean value (SD)				3	1.27 (5.3)	2.46 (2.46)	1.36 (5.5)
BODY WEIGHT DEPENDENT PARAMETERS				5	1.40 (4.5)	2.74 (5.2)	1.60 (4.7)
<i>*Note: All measurements based upon multi-modal images and methods. An average value is reported.</i>				10	1.50 (3.8)	3.27 (3.5)	2.06 (3.1)
				15	1.83 (2.0)	3.71 (2.4)	2.43 (2.1)
				20	2.02 (1.9)	4.14 (2.2)	2.80 (2.0)
Adapted from June Boon, Veterinary Echocardiography, 1998				25	2.18 (2.4)	4.48 (2.9)	3.10 (2.5)
Rishniw M and Hollis NE, J Vet Intern Med 2000; 14:429-435				30	2.33 (3.3)	4.83 (3.9)	3.39 (3.4)
Hansson et al, Vet Rad and Ultrasound 2002				35	2.48 (4.3)	5.17 (5.0)	3.69 (4.5)
Bonagura et al. Echocardiography: principles of interpretation, Vet Clin North Am 15:1177, 1995				40	2.62 (5.2)	5.48 (6.1)	3.96 (5.4)
				50	2.88 (7.1)	6.07 (8.3)	4.46 (7.4)

INTERPRETATION OF THE FINDINGS & FURTHER RECOMMENDATIONS

Chronic degenerative valve disease causing trace/mild mitral regurgitation. Lack of significant left atrial enlargement indicates the current risk for complication is low. No concurrent issues such as systolic dysfunction or pulmonary hypertension are noted in this study.

No cardiac medications are clearly indicated, as no benefit has been shown to providing therapy for dogs in stage B1. Omega fatty acid supplementation and mild salt restriction may be of some long-term benefit. Monitor for development of a progressive cough, labored breathing, exercise intolerance or collapse episodes.



PATIENT

Molly Rivas

Assessment of progression in the future will help predict long term prognosis, which is highly variable with stage B1 disease. Many B1 dogs will remain asymptomatic with slow progression for years to come.

SPECIES

Canine

No cardiac contraindication for general anesthesia prior to chamber enlargement.

BREED

Pub Mix

Recommend conservative monitoring with a recheck echocardiogram in 6-12 months to assess rate of progression, sooner if any development of clinical signs in the interim.

SEX

Female Spayed

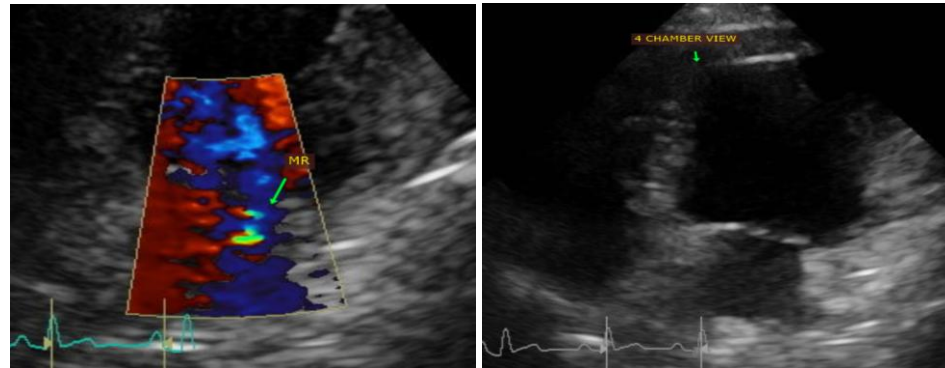
AGE

11.3 years

WEIGHT

48lbs

IMAGES



INTERPRETED BY

Maggie Machen Lamy,
DVM, DACVIM
(Cardiology)

The information and recommendations provided are based on the images presented by the referring veterinarian. No evaluation can be communicated regarding pathology that was not visible in the image/video clips provided.

Thank you for this referral. This report was generated using transcription software, and minor dictation errors may be present. If the clinical or image interpretation does not parallel your findings or if I can be of any further assistance, please contact me.

IMAGING PERFORMED BY

Kelly Romero, DVM

Maggie Machen Lamy, DVM
Diplomate of the American College of Veterinary Internal Medicine (Cardiology)
info@sonopath.com

HOSPITAL NAME

Countryside Animal
Hospital

REFERRING VET

Dr. Latelle

INVOICE

46251

DATE

12/17/25